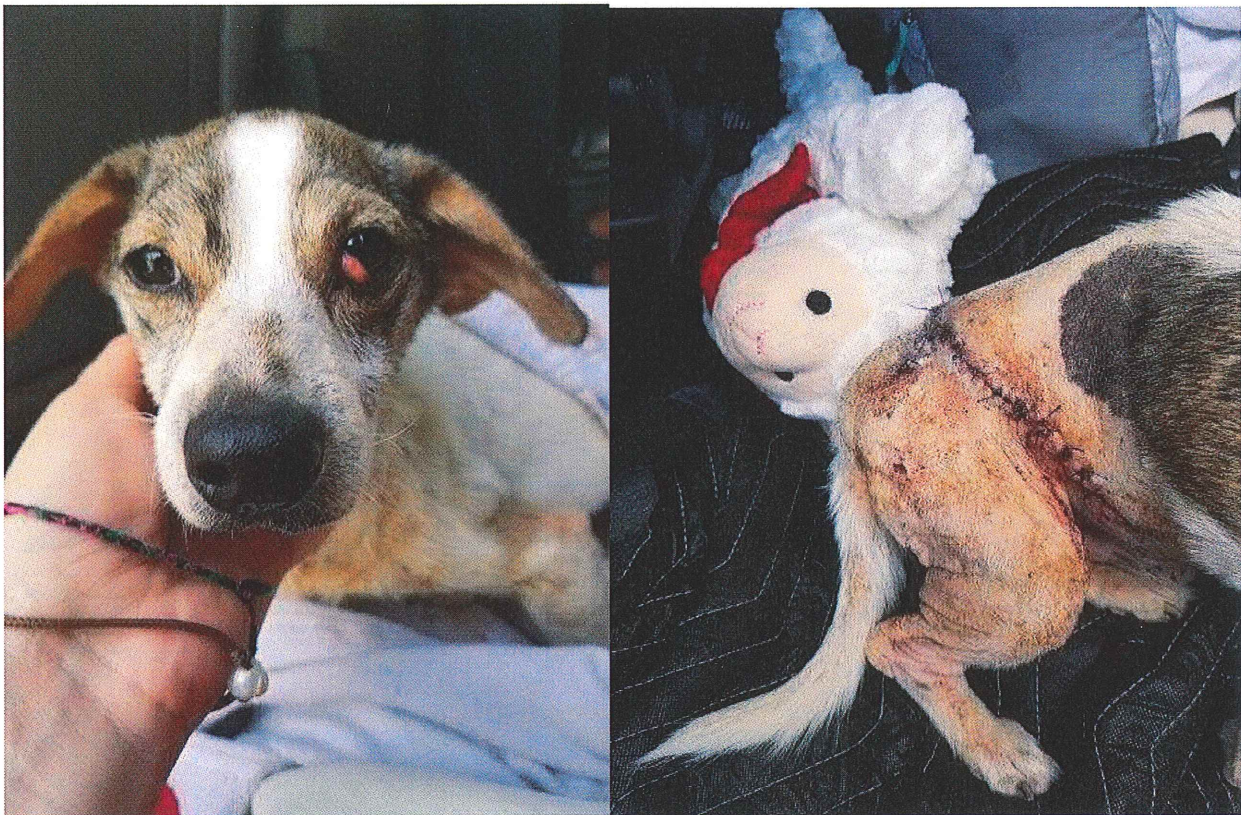

“Frank”

Our department received a call from one of our local vets on June 29th, 2020 in regards to a woman dropping off a dog in poor condition claiming it was a stray and wanting to have it euthanized. An Animal Control officer responded and found the dog to be weak, had a major skin infection and a very large abscess type pocket on his hind end that was oozing fluid and puss, amongst other issues. “Frank” went through hydrotherapy to flush out the abscess and after a few days of IV fluids and antibiotics, the dog had surgery to remove a large amount of dead tissue.



Case #: 20-45859

Treatment: Hydrotherapy, Debridement, Cystotomy, and medications.

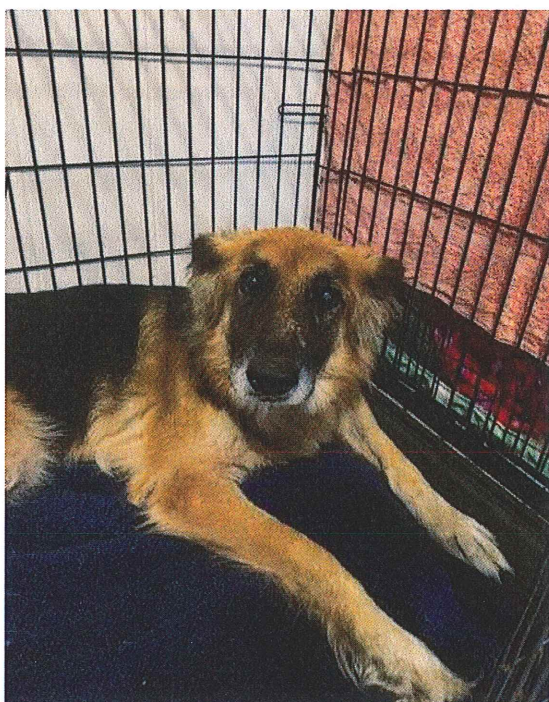
Cost: \$1,531.84

Outcome: Adopted

“Penelope”



On July 1st, 2020 this female German Shepherd was picked up in the as a stray in the area of Stratford Dr. in Port Charlotte. The dog was matted, emaciated, and had an extremely foul odor coming from her, leading us to believe she had an infection. The dog was transported to The Animal Clinic, where it was found that she was suffering from Pyometra, several mammary tumors, and was about 30 lbs underweight. Penelope went through an emergency spay and will be getting her mammary tumors removed when she is of a more appropriate weight.



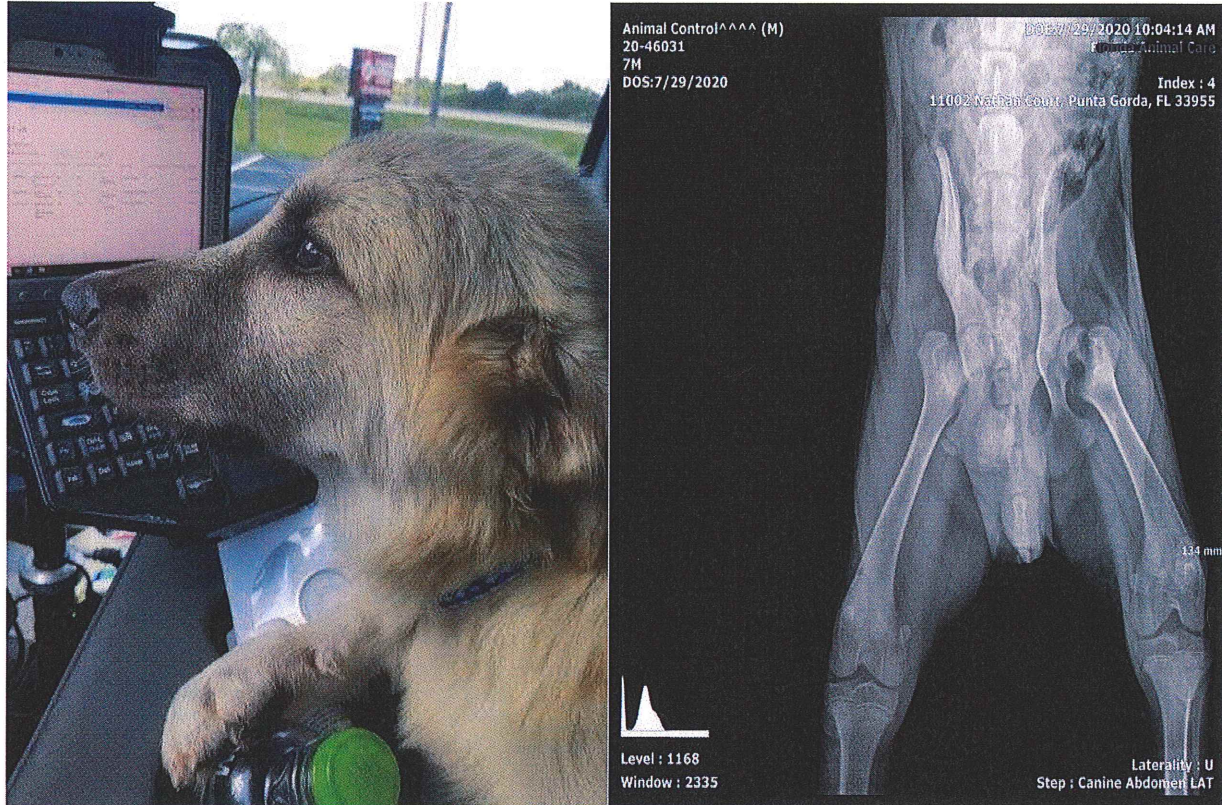
Case #: 20-45877

Treatment: Emergency Spay/Pyometra

Cost: \$1,221.95

Outcome: Adopted

“Wellington”



In July of 2020, our department received a call about a stray puppy that was limping in the area of Oil Well Rd. in Punta Gorda. The Anatolian Shepherd puppy was picked up and brought to a veterinary clinic for examination. Upon examination, it was found that the pup’s pelvis was disfigured due to an old break that was never addressed. As a result of the incorrect healing, the dog was in pain and in need of a surgical procedure called femoral head ostectomy (FHO).

Case #: 20-46031

Treatment: FHO surgery

Cost: \$1,662.76

Outcome: Adopted