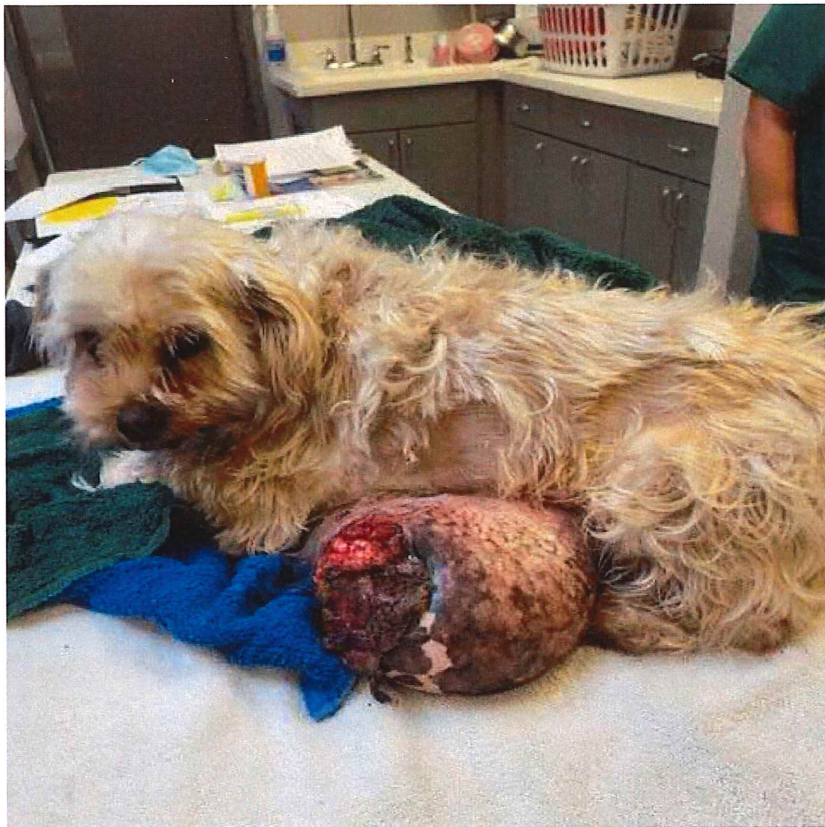

# “CLYDE”

On January 14th, 2022, A stray dog was dropped off to the Animal Welfare League with a giant mass on his abdomen. The mass was ulcerated, infected, and extremely uncomfortable. “Clyde” was transported to Punta Gorda Animal Hospital and was found to also be anemic and in need of a blood transfusion. The vet clinic was able to perform both the mass removal and blood transfusion, which were both successful. “Clyde” was able to make a full recovery and was adopted 2 weeks later.



Case # 22-50114

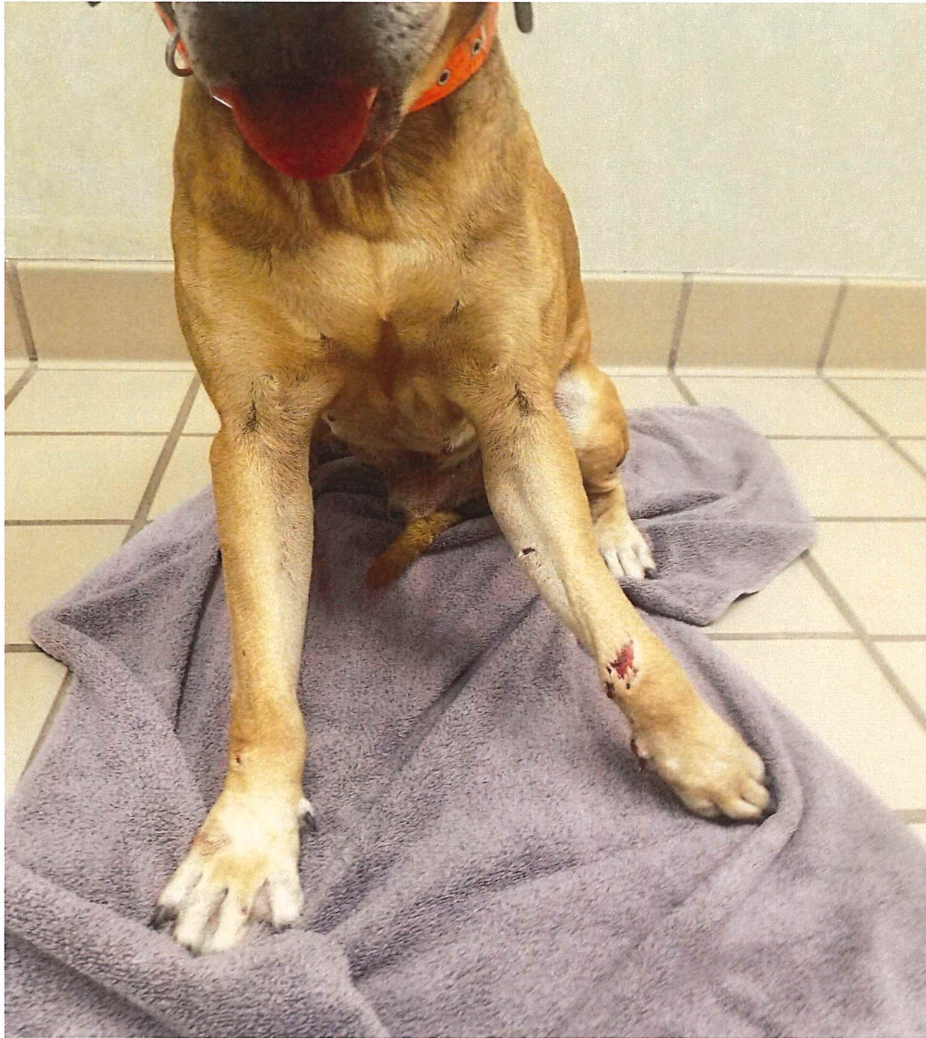
Treatment: Mass removal and blood transfusion

Cost: \$1,634.63

Outcome: Adopted

## “Chenango” “

In January 2022, our department received a call regarding a dog hit by car on US 17. The dog, who we later named “Chenango”, was quickly scooped up and taken to the nearest veterinary hospital. The dog was found to have a fractured leg and road rash. The veterinarian was able to treat the leg fracture and the dog was adopted to a loving home.



Case #: 22-50250

Treatment: stabilization of leg, X-rays, pain meds & antibiotics


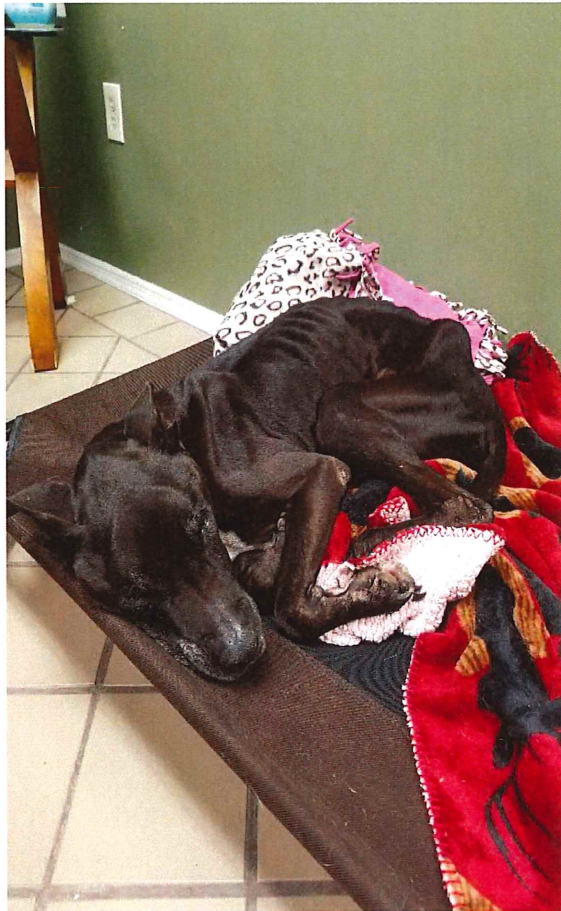
Cost: \$1,265.83

Outcome: Adopted



## “Buddy”

In April 2022, our department responded to a home in regards to animals in poor condition. Several animals were confiscated from the home, including “Buddy”. “Buddy” was extremely emaciated, anemic from a flea infestation, hookworms, and dehydrated. He was treated and cared for by a local veterinarian and was able to live out the rest of his life in a loving home.



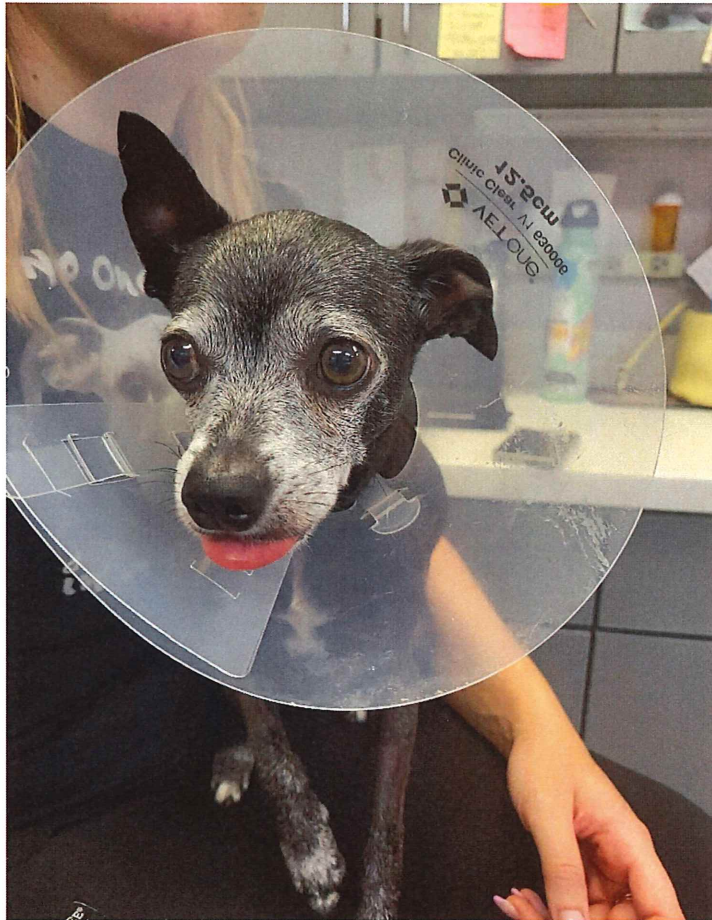
Case #: 22-51026

Treatment: Bloodwork, deworming, & medications

Cost: \$760.55

Outcome: Adopted

# “MOE”



In September 2022, a good Samaritan found a Chihuahua around Zemel Rd in Punta Gorda with deep lacerations along his neck and back. The citizen transported to the dog themselves to the Veterinary Emergency Clinic (VEC) in Port Charlotte. The VEC did not suspect foul play, and believed it was possibly due to crawling under something such as barbed wire. Surgery was done to clean and suture up the wounds, and antibiotics and pain medication were administered.

Our department located the owner of “Moe” and advised him of his injuries. The owner felt it would be best to surrender “Moe” to our department for him to be placed up for adoption.

Case #: 22-51965

Treatment: Blood work, Laceration Repair, antibiotics, and pain meds

Cost: \$3,621.32

Outcome: Transferred to Humane Society of Pinellas County